

Gynecomastia with pseudoangiomatous hyperplasia and multinucleated giant cells in a patient without neurofibromatosis

Michal Zámečník^{1,2}

¹ AGEL Laboratories a.s., Department of Pathology, Nový Jičín, Czech Republic

² Medicyt s.r.o., Laboratory of Pathology, Trenčín, Slovak Republic

Dear Editor:

Pseudoangiomatous stromal hyperplasia (PASH) and stromal multinucleated giant cells (MGC) can occur in both female and male breast (1-5). In males, simultaneous occurrence of PASH and MGC in gynecomastia was described in patients with neurofibromatosis type 1 (NF-1) (6-8). However, the specificity of this finding for NF-1 still remains unclear because the number of

described cases is limited. In male patients without NF-1, PASH with MGC in gynecomastia was not reported, to my knowledge. Here, I would like to describe one such case briefly.

A 22-year-old male presented with two years slowly growing unilateral gynecomastia of the right breast. Otherwise, his medical history was unremarkable. The lesion was excised and

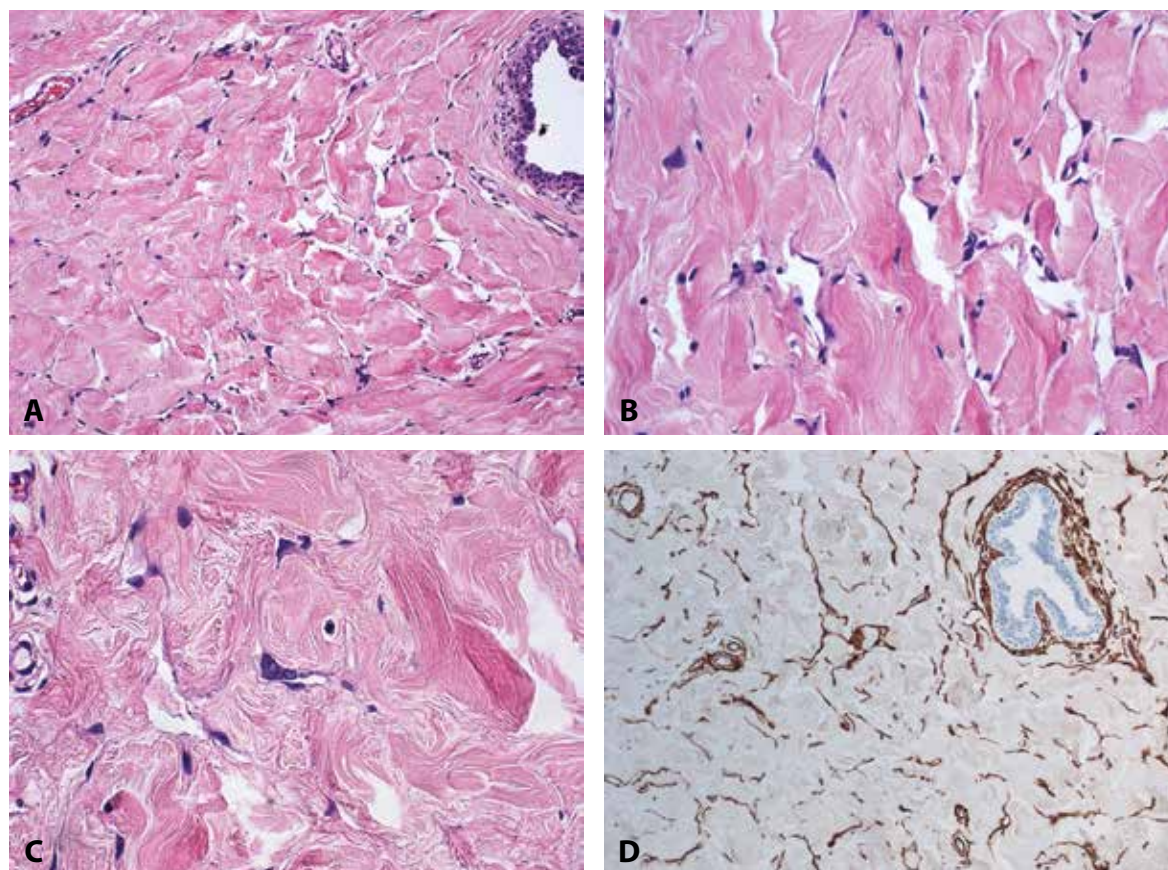


Fig. 1. Gynecomastia with stromal pseudoangiomatous hyperplasia and with multinucleated giant cells. **A-C:** pseudovascular spaces and multinucleated cells in the stroma are shown at low-, medium- and high-power magnifications, respectively. **D:** immunohistochemical expression of CD34 in the stromal cells (hematoxylin and eosin; **A-C:** magnifications x50, x100, and x200, respectively; **D:** SABC technique, magnification x50).

✉ Correspondence address:

Dr. M. Zamecnik

Medicyt, s.r.o.

Legionarska 28, 91171 Trenčín, Slovak Republic

tel.: +421-907-156629

e-mail: zamecnikm@seznam.cz

submitted for histological examination. **Grossly**, it measured 5 x 4 x 2.5 cm, and it was of fibrous appearance. **Histologically**, the lesion showed typical features of gynecomastia, such as hyperplasia of the mammary stroma and of the ducts. 70% of the stroma presented PASH with typical slit-like spaces. In addition, a focus representing 20% of the PASH's volume contained numerous MGC (Fig. 1A-C). **Immunohistochemically**, the mono- and multinucleated stromal cells were positive for vimentin, CD34 (Fig. 1D) and calponin, and they were all negative for estrogen and progesterone receptors (ER, PR), alpha-smooth muscle actin, desmin, caldesmon, CD31, D2-40 and S100 protein. Expression of ER and PR was limited to the ductal epithelium. Histological and immunohistochemical features were identical to those of previously reported cases of gynecomastia with PASH and MGC in patients with NF-1 (6-8). Therefore, we strongly recommended additional clinical examinations focused on a possible underlying diagnosis of neurofibromatosis. Rigorous clinical work-up (dermatologic, ophthalmologic, neurological

and internist examinations) excluded a possibility of NF-1. The patient is well 5 months after the surgery.


Our case indicates that finding of PASH with MGC in gynecomastia may not be always associated with neurofibromatosis, although all cases reported previously demonstrated this association. In patients without NF-1, the finding of MGC in gynecomastia is rare (3,5), but PASH itself is quite common with reported frequency up to 47.4 % of cases (5). Therefore, incidental simultaneous occurrence of PASH and MGC should not be surprising, although its frequency is certainly low and determined mainly by the rarity of MGC. In the present case, the finding of MGC in PASH was focal, whereas it was either diffuse or its extent was not explicitly mentioned in the reports of NF-1 associated cases (6-8). I suppose that focal PASH with MGC might have a lower specificity for NF-1 in comparison with cases with the diffuse stromal involvement, but the evidence remains very limited. Future studies of cases similar to the one reported here could bring more accurate information about this specificity.

REFERENCES

1. **Vuitch MF, Rosen PP, Erlandson RA.** Pseudoangiomatous hyperplasia of mammary stroma. *Hum Pathol* 1986; 17: 185-191.
2. **Rosen P.** Multinucleated mammary stromal giant cells. A benign lesion that simulates invasive carcinoma. *Cancer* 1979; 44: 1305-1308.
3. **Campbell AP.** Multinucleated stromal giant cells in adolescent gynaecomastia. *J Clin Pathol* 1992; 45: 443-444.
4. **Zámečník M, Dubač V.** Pseudoangiomatous stromal hyperplasia with giant cells in the female breast. No association with neurofibromatosis? *Cesk Patol* 2011; 47: 59-61.
5. **Badve S, Sloane JP.** Pseudoangiomatous hyperplasia of male breast. *Histopathology* 1995; 26: 463-466.
6. **Damiani S, Eusebi V.** Gynecomastia in type-1 neurofibromatosis with features of pseudoangiomatous stromal hyperplasia with giant cells. Report of two cases. *Virchows Arch* 2001; 438: 513-516.
7. **Zámečník M, Michal M, Gogora M, Muken-šnabl P, Dobiáš V, Vano M.** Gynecomastia with pseudoangiomatous stromal hyperplasia and multinucleated giant cells. Association with neurofibromatosis type 1. *Virchows Arch* 2002; 441: 85-87.
8. **Kimura S, Tanimoto A, Shimajiri S, et al.** Unilateral gynecomastia and pseudoangiomatous stromal hyperplasia in neurofibromatosis: case report and review of the literature. *Pathol Res Pract* 2012; 208: 318-322.

OSOBNÍ SDĚLENÍ

Prof. MUDr. Zdeněk Nožička, DrSc.



Dne 27. října 2013 zemřel ve věku 81 let prof. MUDr. Zdeněk Nožička, DrSc., pracovník Fingerlandova ústavu patologie v Hradci Králové od roku 1962. CV prof. Nožičky vyšlo k výročí jeho 80. narozenin v 1. čísle Česko-slovenské patologie 2013.

Vzpomínáme !

I. Šteiner