

## DOUBLE IMMUNOSTAINING WITH CD1A AND CD68 IN THE PHENOTYPIC CHARACTERIZATION OF INDETERMINATE CELL HISTIOCYTOSIS

Fernandez-Flores A., Manjon J.A. <sup>2</sup>, Manzarbeitia F. <sup>3</sup>

From the Services of <sup>1</sup>Anatomic Pathology and <sup>2</sup>Dermatology, Hospital El Bierzo, Fuentesnuevas, Ponferrada, Spain, the <sup>1</sup>Service of Cellular Pathology, Clinica Ponferrada, Ponferrada, Spain, and the <sup>3</sup>Department of Anatomic Pathology, Fundación Jimenez Diaz, Universidad Autonoma de Madrid, Madrid, Spain

### Summary

Indeterminate cell histiocytosis (ICH) is a rare disorder in which histiocytic cells proliferate, expressing markers of both X- and non-X histiocytosis. Nevertheless, it is not totally clear if both types of markers are co-expressed by the same cell in this disorder, or on the contrary, the histiocytosis is made of two phenotypically different types of cells. Some recent reports seem to indicate this latter option, since there is a non-homogeneous distribution of the cells in the dermis. The ones in the most superficial part of the biopsy would lose some of their markers when moving towards the bottom part of the dermis. In order to check if there is co-expression of CD1a and CD68 by the same cell, we performed an immunohistochemical study with double staining, in a case of ICH of a 74-year-old male, who presented multiple yellowish papules in chest, back and both arms. Their sizes varied between 1 and 3 mm.

One of the biopsies from one lesion of the back showed a dermal histiocytic infiltrate, which expressed S-100, CD1a, Factor XIIIa and CD68 in the common immunohistochemical study. Birbeck granules were not found in the ultrastructural study.

Our results with the double stain for CD1a and CD68 demonstrated that most of the histiocytes expressed either one marker or the other. Nevertheless, some of the histiocytes of the infiltrate co-expressed both markers. In all the cases, the cells with this combined phenotype were mononuclear. Although CD1a was mainly expressed by the cells at the top of the dermis, some cells of the deep dermis kept expressing this marker. The cells expressing both markers were mostly found in the top part of the dermis. The multinucleate cells expressed only CD68, but not CD1a.

**Key words:** indeterminate cell histiocytosis – Langerhans' cell – CD1a – CD68 – S-100

### Souhrn

#### Dvojité imunohistochemické barvení CD1a a CD68 pro fenotypickou charakteristiku histiocytózy z neurčených buněk

Histiocytóza z neurčených buněk (Indeterminate cell histiocytosis – ICH) je vzácná choroba, kdy proliferační histiocytární buňky exprimují znaky jak X-, tak non-X histiocytózy. Nicméně není zcela jasné, zda oba typy znaků jsou společně exprimovány jedním typem buněk, či naopak, histiocytóza je tvořena dvěma fenotypicky rozličnými typy buněk. Některé novější práce se přiklání spíše ke druhému z uvedených eventualit, protože rozložení buněk v kůři je nehomogenní. Buňky v nejvšchnějších vrstvách biopsie by ztrácely část svých znaků při svém pohybu do hlubších vrstev koria. Abychom zjistili, zda dochází ke koexpresi CD1 a CD68 jedním typem buněk, provedli jsme dvojitě imunohistochemické barvení v případě ICH u 74letého muže s mnohočetnými žlutavými papulemi na hrudi, zádech a obou pažích. Velikost papul byla 1–3 mm. V biopsii jedné z lézí zad byl v kůři infiltrát z histiocytů, které v rutinní imunohistochemii exprimovaly S-100, CD1a, faktor XIIIa a CD68. Elektronová mikroskopie nezjistila přítomnost Birbeckových granulí.

Naše studie s dvojitým barvením CD1a a CD68 prokázala, že většina histiocytů exprimovala buď jeden nebo druhý znak. Nicméně, některé z histiocytů v infiltrátu exprimovaly společně oba znaky. Všechny buňky s tímto kombinovaným fenoménem byly jednojaderné. I když exprese CD1a byla charakteristická převážně pro buňky v povrchu koria, ojediněle se nacházela i u buněk v hlubokém kůři. Buňky exprimující oba znaky se nacházely většinou v povrchových vrstvách. Mnohojaderné buňky exprimovaly pouze CD68, nikoli ale CD1a.

**Klíčová slova:** histiocytóza z neurčených buněk – Langerhansovy buňky – CD1a – CD68 – S-100

*Čes.-slov. Patol., 44, 2008, No. 2, p. 37–39*

### INTRODUCTION

Indeterminate cell histiocytosis (ICH) is alleged to be made of histiocytes that express some markers that are characteristic of Langerhans' cell histiocytosis, as well as markers which are typical of non-Langerhans' cell histiocytosis.

Nevertheless, when evaluating some of the reports in

literature, in which immunohistochemical studies have been performed on ICH, many clues seem to indicate that although most of the cells express S-100 protein, there are two different populations of cells: one which expresses CD1a, and the other one which expresses CD68. Some reports have remarked how the CD1a-positive cells are mainly found in the top parts of the dermis, while the CD68-positive cells are found in deeper areas of the dermis (8). Nevertheless, there is no direct evidence, that the cells

expressing CD1a and the ones expressing CD68 are different. In order to test the hypothesis that ICH is really made of two phenotypically different populations of cells, we performed a double immunostain in a biopsy of an ICH case. The antibodies for CD1a and CD68 were used on the same section. Each antibody was revealed with a different chromogen, so it could be tested if the expression of CD1a and CD68 was present in the same cells or in different ones.

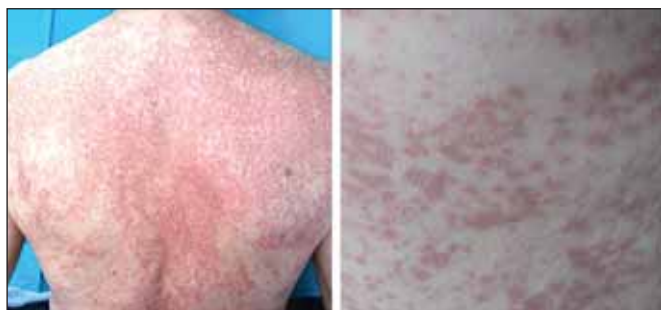

Fig. 1. Skin eruption shown by the patient. On the right a closer view of the lesions can be seen

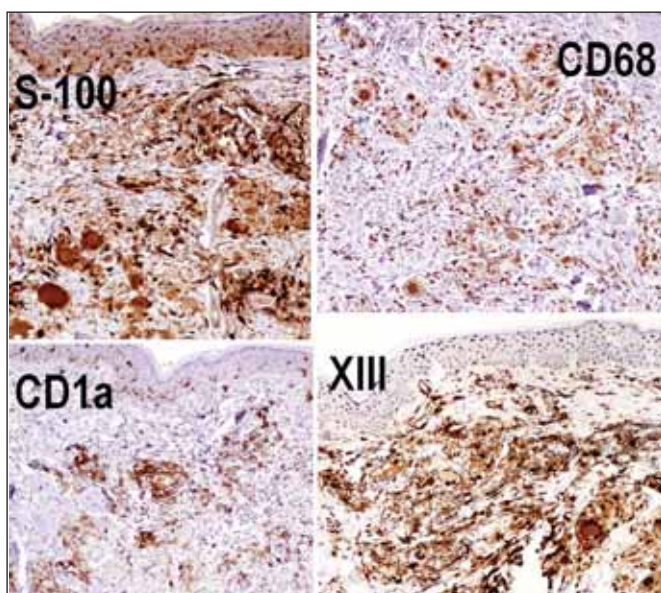


Fig. 3. The picture shows the immunoexpression of S-100 (top-left), CD68 (top-right), CD1a (bottom left) and factor XIII (bottom right) by the histiocytic infiltrate

## MATERIALS AND METHODS

A 74-year-old man came to the consultancy due to some lesions that he had noticed on the trunk since 4 months ago. We performed two biopsies of two lesions from the back of the patient. One of them was studied by conventional microscopy and the other by electronic microscopy. The first one was fixed in formaldehyde and processed under the routine protocol for biopsies and embedded in paraffin, and sections for hematoxylin-eosin and Giemsa were obtained. Sections for immunohistochemistry were also obtained using the Dako REAL EnVision detection system, peroxidase/diaminonenzidine (DAB)+, rabbit/mouse, for CD1a (DakoCytomation, monoclonal mouse anti-human, clone 010, code M351), Factor XIIIa (Master Diagnostica S.L., Granada, clone AC-1A1), CD68 (DakoCytomation, monoclonal mouse anti-human, clone PG-M1, code

N1576), and S-100 (DakoCytomation, rabbit anti-cow, code N1517).

An immunohistochemical study for double staining was also performed with CD1a and CD68. While the immunostaining for CD1a was revealed with DAB (brown color), the one for CD68 was revealed with aminoethylcarbazole (red color).

The second biopsy was fixed in glutaraldehyde, and sections were obtained and studied under electronic microscope.

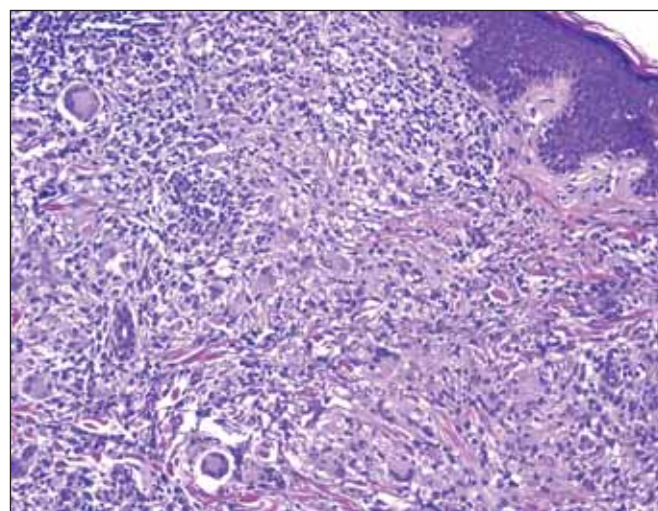


Fig. 2. Histiocytic dermal infiltrate composed of mononuclear as well as of multinuclear cells

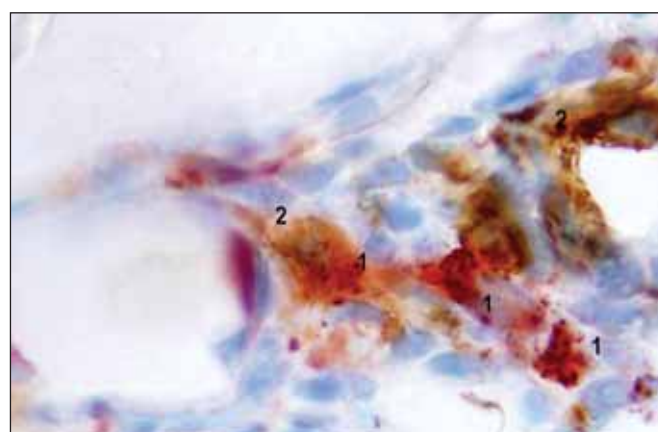


Fig. 4. Double immunostaining of the histiocytic infiltrate for CD68 (number 1, stained in red) and CD1a (number 2, stained in brown). While some cells only expressed either one or the other, some others expressed both markers, as shown in the figure

## RESULTS

The examination of the patient revealed multiple yellowish papules on the chest, the back and both arms (Fig. 1). They measured between 1 and 3 mm.

The routine morphologic study demonstrated a histiocytic dermal infiltrate, made of mononuclear, as well as of multinuclear cells (Fig. 2), with focal and mild emperipolesis of lymphocytes by multinucleated cells.

The immunohistochemical study demonstrated that most of the cells expressed S-100 protein and (in a slightly smaller proportion) CD68 and factor XIIIa (in both mononuclear and multinucleate histiocytes). CD1a was expressed by mononuclear but not by polynuclear histiocytes. Although cells expressing CD1a were more numerous in the superficial dermis, they were also common in the deep dermis (Fig.3).



When the double-staining method was used, the results showed that most of the histiocytes of the infiltrate expressed either CD68 or CD1a. Nevertheless, some histiocytes co-expressed both markers (Fig.4). In all cases, the cells with this combined phenotype were mononuclear. Although CD1a was mainly expressed by cells at the top of the dermis, some cells of the deep dermis kept expressing this marker. The cells expressing both markers were mostly found in the top part of the dermis.

The ultrastructural study did not show any evidence of Birbeck granules.

---

## DISCUSSION

---

Intermediate cell histiocytosis (ICH) was first described in 1985 (10) referring to a disorder made of cells that expressed both CD1a and S-100, and that lacked Birbeck granules in the ultrastructural study. Nevertheless, since electronic microscopy is not so commonly used nowadays in the diagnosis of this entity, the name is usually used to refer to a histiocytic disorder in which cells shared macrophage- as well as Langerhans' cell-markers (1, 2, 8).

The disorder is considered to be made of indeterminate cells. In the past, the latter were supposed precursors of the epidermal/dermal dendritic cell system (4), but are at present considered more as members of the cutaneous dendritic system, which would be on their way to the regional lymph nodes (7, 8). They are especially prominent in proliferating epidermis, as well as in mucous membranes (3).

The immunophenotypic hallmark of indeterminate histiocytosis has been alleged to be the coexistence of features of both X- and non X-histiocytosis (8). Among the non-X-histiocytosis markers, macrophage markers such as CD68 or HAM 56 have been proved to be expressed by IHC cells (6). CD68 is traditionally considered as "not expressed" by Langerhans' cell (LC) histiocytosis, although sometimes LC can express it (5). In this latter case, the intensity of the expression is lower than the one which is shown by macrophages (5). Among the X-histiocytosis-markers which are expressed by IHC cells, one can mention CD1a and CD1c. S-100 protein (usually expressed by Langerhans' cells) is also mentioned sometimes as a crucial marker in the diagnosis of ICH (8). Nevertheless, it can also be expressed by non-Langerhans' cell histiocytosis (5, 9), CD1a seems to be more specific; although it can occasionally be expressed by non-Langerhans' cell histiocytosis; in these latter disorders the form of expression is weak and focal (5).

The presence of emperipolesis, to a certain limit, is not incompatible with the diagnosis of ICH (5). Although it has been admitted that if prominent inflammatory infiltrate plus emperipolesis are seen, some of these lesions would be better considered as sinus histiocytosis with massive lymphadenopathy (5), the latter is usually CD1a negative.

In spite of the importance of the expression of both types of markers by the cell of ICH in the diagnosis of this entity, some clues in literature seemed to indicate a sort of zonation phenomenon in the expression of immunological markers. For instance, while S-100 and CD45 are expressed by the majority of the cells in the lesions, CD68 and CD1a seemed to be expressed only by a percentage of cells (6). Moreover, CD1 is mainly expressed by cells of the superficial dermis while the infiltrate in the lower dermis is reactive for a variety of macrophage markers (8). Some authors interpret this peculiar distribution as a loss of histiocytosis markers, from the surface to the deep parts of the dermis, which would be due to the

unphysiological conditions of the skin for cells which should be present in the lymph node (8).

Our report shows that at least some of the cells co-express both markers. It also shows that the histiocytes that do so, are mainly located in the top part of the dermis. The current findings are not necessarily contradictory to previous reports which suggest a change in the phenotype of the histiocytes from the top to the bottom parts of the dermis. It just shows that, in case such change really exists, there is at least an intermediate stage in which cells co-express X and non-X histiocytic markers.

## Acknowledgements

*We would like to thank Dr. Miguel Angel Martínez González from the University Hospital Doce de Octubre (Madrid, Spain) for having performed the ultrastructural study of one of the biopsies for us. We also want to thank Mrs Trinidad Carrizosa (Fundacion Jimenez Diaz, Madrid, Spain), for having performed the double-staining technique, and Mrs Manoli Sánchez Fernández (Hospital El Bierzo) for the beautiful immunohistochemical stains.*

---

## REFERENCES

---

1. **Berti, E., Gianotti, R., Alessi, E.:** Unusual cutaneous histiocytosis expressing an intermediate immunophenotype between Langerhans cells and dermal macrophages. *Arch. Dermatol.*, 124: 1250-1253, 1988.
2. **Kolde, G., Brocker, E.B.:** Multiple skin tumors of indeterminate cells in an adult. *J. Am. Acad. Dermatol.*, 15: 591-597, 1986.
3. **Lessard, R.J., Wolff, K., Winkelmann, R.K.:** The disappearance and regeneration of Langerhans cells following epidermal injury. *J. Invest. Dermatol.*, 50: 171-179, 1968.
4. **Murphy, G.F., Bahn, A.K., Harist, T.J., Mihm, M.C. Jr.:** In situ identification of T6-positive cells in normal human dermis by immunoelectron microscopy. *Br. J. Dermatol.*, 108: 423-431, 1983.
5. **Ratzinger, G., Burgdorf, W.H.C., Metze, D., Zelger, B.G., Zelger, B.:** Indeterminate cell histiocytosis: fact or fiction? *J. Cutan. Pathol.*, 32: 552-560, 2003.
6. **Rodríguez-Jurado, R., Vidaurri-de la Cruz, H., Durán-Mckinster, C., Ruiz-Maldonado, R.:** Indeterminate cell histiocytosis: clinical and pathologic study in a pediatric patient. *Arch. Pathol. Lab. Med.*, 127: 748-751, 2003.
7. **Romani, G., Schuler, G.:** The immunologic properties of epidermal Langerhans cell as a part of the dendritic cell system. *Springers. Semin. Immunopathol.*, 13: 265-279, 1992.
8. **Sidoroff, A., Zelger, B., Steiner, H., Smith, N.:** Indeterminate cell histiocytosis- a clinicopathological entity with features of both X- and non-X histiocytosis. *Br. J. Dermatol.*, 134: 525-532, 1996.
9. **Tomaszewski, M.M., Lupton, G.P.:** Unusual expression of S-100 protein in histiocytic neoplasms. *J. Cutan. Pathol.*, 25:129-135, 1998.
10. **Wood, G.S., Hu, C.H., Beckstead, J.H., Turner, R.R., Winkelmann, R.K.:** The indeterminate cell proliferative disorder: report of a case manifesting as an unusual cutaneous histiocytosis. *J. Dermatol. Surg. Oncol.*, 11: 1111-1119, 1985.

*Corresponding author:*

*Angel Fernandez-Flores, MD, PhD  
S. Patología Celular, Clinica Ponferrada  
Avenida Galicia 1  
24400 Ponferrada  
Spain*

*Telephone: (00 34) 987 42 37 32*

*Fax: (00 34) 987 42 91 02*

*e-mail: gpyauflowerlion@terra.es*